

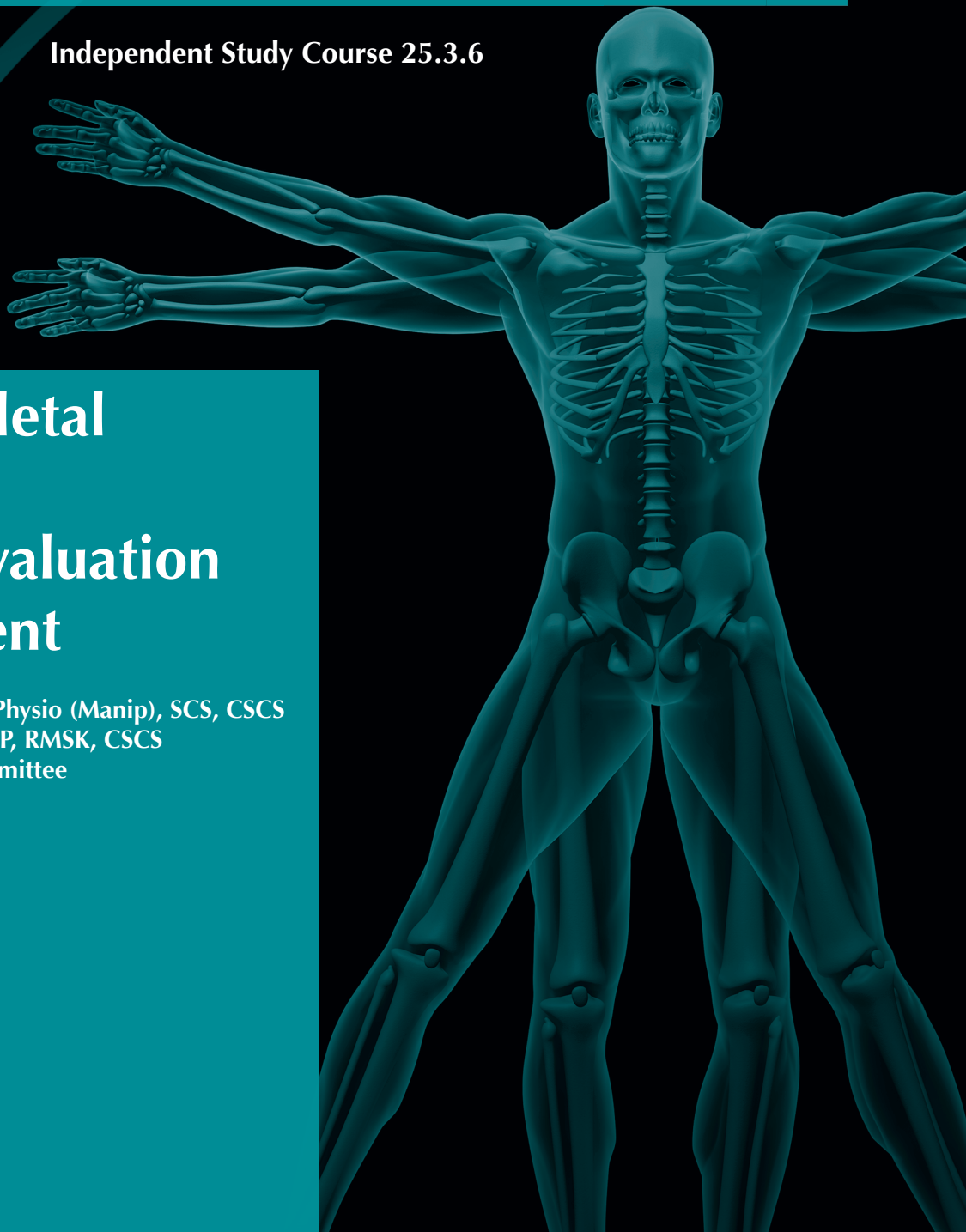

Alternative Special Topics:

Innovations in Practice

Independent Study Course 25.3.6

Musculoskeletal Ultrasound: Its Use in Evaluation and Treatment

Amber Donaldson, DPT, M Physio (Manip), SCS, CSCS
Dustin Nabhan, DC, DACBSP, RMSK, CSCS
United States Olympic Committee
Colorado Springs, Colorado



REFERENCES

1. Goldberg BB, Gramiak R, Freimanis AK. Early history of diagnostic ultrasound: the role of American radiologists. *AJR Am J Roentgenol*. 1993;160:189-194.
2. Kimmelman B. *Medical Diagnostic Ultrasound: A Retrospective on Its 40th Anniversary*. AIUM. Washington, D.C.; 1988.
3. Whittaker J. *Ultrasound Imaging for Rehabilitation of the Lumbopelvic Region; a Clinical Approach*. London, United Kingdom; 2007.
4. Abu-Zidan FM, Hefny AF, Corr P. Clinical ultrasound physics. *J Emerg Trauma Shock*. 2011;4:501-503. doi: 10.4103/0974-2700.86646
5. Dean T. Scalable Neuroscience and the Brain Activity Mapping Project. <http://cs.brown.edu/people/tld/note/blog/13/04/19/>. Accessed April 19, 2014.

6. Hollister MS, Mack LA, Patten RM, et al. Association of sonographically detected subacromial/subdeltoid bursal effusion and intraarticular fluid with rotator cuff tear. *AJR Am J Roentgenol*. 1995;165:605-608.
7. van Holsbeeck M, Strouse PJ. Sonography of the shoulder: evaluation of the subacromial-subdeltoid bursa. *AJR Am J Roentgenol*. 1993;160:561-564.
8. Jacobson JA. Shoulder US: anatomy, technique, and scanning pitfalls. *Radiology*. 2011;260:6-16. doi: 10.1148/radiol.11101082.
9. Chipman JN, Mott RT, Stanton CA, et al. Ultrasonographic Tinel sign. *Muscle Nerve*. 2009;40:1033-1035. doi: 10.1002/mus.21461
10. Klauser AS, Halpern EJ, De Zordo T, et al. Carpal tunnel syndrome assessment with US: value of additional cross-sectional area measurements of the median nerve in patients versus healthy volunteers. *Radiology*. 2009;250:171-177. doi: 10.1148/radiol.2501080397
11. Jones MH, England SJ, Muwanga CL, et al. The use of ultrasound in the diagnosis of injuries of the ulnar collateral ligament of the thumb. *J Hand Surg Br*. 2000;25:29-32.
12. Bierma-Zeinstra SM, Bohnen AM, Verhaar JA, et al. Sonography for hip joint effusion in adults with hip pain. *Ann Rheum Dis*. 2000;59:178-182.
13. Kong A, Van der Vliet A, Zadow S. MRI and US of gluteal tendinopathy in greater trochanteric pain syndrome. *Eur Radiol*. 2007;17:1772-1783.
14. Puranen J, Orava S. The hamstring syndrome--a new gluteal sciatica. *Ann Chir Gynaecol*. 1991;80:212-214.
15. De Luigi AJ, Nabhan D, Moreau W. Early sonographic detection of a talar dome osteochondral defect in a female wrestler. *Curr Sports Med Rep*. 2014;13(3):169-171. doi: 10.1249/JSR.0000000000000051
16. Kainberger FM, Engel A, Barton P, et al. Injury of the Achilles tendon: diagnosis with sonography. *AJR Am J Roentgenol*. 1990;155:1031-1036.
17. Torriani M, Kattapuram SV. Technical innovation. Dynamic sonography of the forefoot: the sonographic Mulder sign. *AJR Am J Roentgenol*. 2003;180(4):1121-1123.
18. Van Eerd M, Patijn J, Sieben JM, et al. Ultrasonography of the cervical spine: an in vitro anatomical validation model. *Anesthesiology*. 2014;120:86-96. doi: 10.1097/ALN.0000000000000006.
19. AIUM. Training Guidelines for Physicians and Chiropractors Who Evaluate and Interpret Diagnostic Musculoskeletal Ultrasound Examinations. <http://www.aium.org/resources/viewStatement.aspx?id=51>. Accessed April 19, 2014.
20. Daley EL, Bajaj S, Bisson LJ, et al. Improving injection accuracy of the elbow, knee, and shoulder: does injection site and imaging make a difference? A systematic review. *Am J Sports Med*. 2011;39:656-662. doi: 10.1177/0363546510390610.
21. Jose J, Silverman E, Kaplan L. Symptomatic ganglion cyst of the popliteus tendon treated with ultrasound-guided aspiration and steroid injection: a case report. *Sports Health*. 2011;3(4):393-395.
22. Saboeiro GR, Sofka CM. Ultrasound-guided ganglion cyst aspiration. *HSS J*. 2008;4(2):161-163.
23. Douglas RJ. Aspiration and injection of the knee joint: approach portal. *Knee Surg Relat Res*. 2014;26(1):1-6. doi: 10.5792/ksrr.2014.26.1.1.
24. Hollander JL. Intra-articular hydrocortisone in the treatment of arthritis. *Ann Intern Med*. 1953;39(4):735-746.
25. Davidson J, Jayaraman S. Guided interventions in musculoskeletal ultrasound: what's the evidence? *Clin Radiol*. 2011;66(2):140-152. doi: 10.1016/j.crad.2010.09.006.
26. Jones A, Regan M, Ledingham J, Patrick M, Manhire A, Doherty M. Importance of placement of intra-articular steroid injections. *BMJ*. 1993;307:1329-1330.
27. Eustace JA, Brophy DP, Gibney RP, Bresnihan B, FitzGerald O. Comparison of the accuracy of steroid placement with clinical outcome in patients with shoulder symptoms. *Ann Rheum Dis*. 1997;56:59-63.
28. Nguyen RT, Borg-Stein J, McInnis K. Applications of platelet-rich plasma in musculoskeletal and sports medicine: an evidence-based approach. *PM R*. 2011;3:226-250. doi: 10.1016/j.pmrj.2010.11.007.
29. Vas J, Méndez C, Perea-Milla E, et al. Acupuncture as a complementary therapy to the pharmacological treatment of osteoarthritis of the knee: randomised controlled trial. *BMJ*. 2004;329:1216.
30. James SL, Ali K, Pocock C, et al. Ultrasound guided dry needling and autologous blood injection for patellar tendinosis. *Br J Sports Med*. 2007;41(8):518-521.
31. Maxwell NJ, Ryan MB, Taunton JE, et al. Sonographically guided intratendinous injection of hyperosmolar dextrose to treat chronic tendinosis of the Achilles tendon: a pilot study. *AJR Am J Roentgenol*. 2007;189:W215-W220.
32. Rabago D, Patterson JJ, Mundt M, et al. Dextrose prolotherapy for knee osteoarthritis: a randomized controlled trial. *Ann Fam Med*. 2013;11:229-237. doi: 10.1370/afm.1504.
33. Rabago D, Lee KS, Ryan M, et al. Hypertonic dextrose and morrhuate sodium injections (prolotherapy) for lateral epicondylitis (tennis

- elbow): results of a single-blind, pilot-level, randomized controlled trial. *Am J Phys Med Rehabil.* 2013;92:587-596. doi: 10.1097/PHM.0b013e31827d695f.
34. Khan SA, Kumar A, Varshney MK, et al. Dextrose prolotherapy for recalcitrant coccygodynia. *J Orthop Surg (Hong Kong).* 2008;16:27-29.
35. Ryan MB, Wong AD, Gillies JH, et al. Sonographically guided intratendinous injections of hyperosmolar dextrose/lidocaine: a pilot study for the treatment of chronic plantar fasciitis. *Br J Sport Med.* 2009;43:303-306. doi: 10.1136/bjism.2008.050021.
36. Kim E, Lee H. The effects of deep abdominal muscle strengthening exercises on respiratory function and lumbar stability. *J Phys Ther Sci.* 2013;25:663-665. doi: 10.1589/jpts.25.663.
37. Chiavaras MM, Jacobson JA. Ultrasound-guided tendon fenestration. *Semin Musculoskelet Radiol.* 2013;17:85-90. doi: 10.1055/s-0033-1333942.
38. Testa V, Capasso G, Maffulli N, Bifulco G. Ultrasound-guided percutaneous longitudinal tenotomy for the management of patellar tendinopathy. *Med Sci Sports Exerc.* 1999;31:1509-1515.
39. Testa V, Capasso G, Benazzo F, et al. Management of Achilles tendinopathy by ultrasound-guided percutaneous tenotomy. *Med Sci Sports Exerc.* 2002;34:573-580.
40. Housner JA, Jacobson JA, Misko R. Sonographically guided percutaneous needle tenotomy for the treatment of chronic tendinosis. *J Ultrasound Med;* 2009;28:1187-1192.
41. McShane JM, Shah VN, Nazarian LN. Sonographically guided percutaneous needle tenotomy for treatment of common extensor tendinosis in the elbow: is a corticosteroid necessary? *J Ultrasound Med.* 2008;27:1137-1144.
42. Watts AE, Yeager AE, Kopyov OV, et al. Fetal derived embryonic-like stem cells improve healing in a large animal flexor tendonitis model. *Stem Cell Res Ther.* 2011;2:4. doi: 10.1186/scrt45.
43. Casanueva B, Rivas P, Rodero B, et al. Short-term improvement following dry needle stimulation of tender points in fibromyalgia. *Rheumatol Int.* 2014;34:861-866. doi: 10.1007/s00296-013-2759-3.
44. Lewit K. The needle effect in the relief of myofascial pain. *Pain.* 1979;6:83-90.
45. Dunning J, Butts R, Mourad F, et al. Dry needling: a literature review with implications for clinical practice guidelines. *Phys Ther Rev.* 2014;19:252-265.
46. Witt CM, Jena S, Brinkhaus B, et al. Acupuncture in patients with osteoarthritis of the knee or hip: a randomized, controlled trial with an additional nonrandomized arm. *Arthritis Rheum.* 2006;54(11):3485-3493.
47. Mavrommatis CI, Argyra E, Vadalouka A, et al. Acupuncture as an adjunctive therapy to pharmacological treatment in patients with chronic pain due to osteoarthritis of the knee: A 3-armed, randomized, placebo-controlled trial. *Pain.* 2012;153:1720-1726. doi: 10.1016/j.pain.2012.05.005.
48. Scharf HP, Mansmann U, Streitberger K, et al. Acupuncture and knee osteoarthritis: a three-armed randomized trial. *Ann Intern Med.* 2006;145:12-20.
49. Witt C, Brinkhaus B, Jena S, et al. Acupuncture in patients with osteoarthritis of the knee: a randomised trial. *Lancet.* 2005;366:136-143.
50. Yang CP, Hsieh CL, Wang NH, et al. Acupuncture in patients with carpal tunnel syndrome: a randomized controlled trial. *Clin J Pain.* 2009;25:327-333. doi: 10.1097/AJP.0b013e318190511c.
51. Yang CP, Wang NH, Li TC, et al. A randomized clinical trial of acupuncture versus oral steroids for carpal tunnel syndrome: a long-term follow-up. *J Pain.* 2011;12:272-279. doi: 10.1016/j.jpain.2010.09.001.
52. Sim H, Shin BC, Lee MS, et al. Acupuncture for carpal tunnel syndrome: a systematic review of randomized controlled trials. *J Pain.* 2011;12:307-314. doi: 10.1016/j.jpain.2010.08.006.
53. Coeytaux RR, Kaufman JS, Kaptchuk TJ, et al. A randomized, controlled trial of acupuncture for chronic daily headache. *Headache.* 2005;45:1113-1123.
54. Shen YF, Younger J, Goddard G, et al. Randomized clinical trial of acupuncture for myofascial pain of the jaw muscles. *J Orofac Pain.* 2009;23:353-359.
55. Smith P, Mossdrop D, Davies S, et al. The efficacy of acupuncture in the treatment of temporomandibular joint myofascial pain: a randomised controlled trial. *J Dent.* 2007;35:259-267.
56. Gonzalez-Perez LM, Infante-Cossio P, Granados-Nuñez M, et al. Treatment of temporomandibular myofascial pain with deep dry needling. *Med Oral Patol Oral Cir Bucal.* 2012;17:e781-e785.
57. Tough EA, White AR, Cummings TM, et al. Acupuncture and dry needling in the management of myofascial trigger point pain: a systematic review and meta-analysis of randomised controlled trials. *Eur J Pain.* 2009;13:3-10. doi: 10.1016/j.ejpain.2008.02.006.
58. Irnich D, Behrens N, Gleditsch JM, et al. Immediate effects of dry needling and acupuncture at distant points in chronic neck pain: results of a randomized, double-blind, sham-controlled crossover trial. *Pain.* 2002;99:83-89.
59. Ingber RS. Shoulder impingement in tennis/

- racquetball players treated with subscapularis myofascial treatments. *Arch Phys Med Rehabil.* 2000;81:679-682.
60. Osborne NJ, Gatt IT. Management of shoulder injuries using dry needling in elite volleyball players. *Acupunct Med.* 2010;28:42-45. doi: 10.1136/aim.2009.001560.
 61. Gunn CC, Millbrandt WE, Little AS, et al. Dry needling of muscle motor points for chronic low-back pain: a randomized clinical trial with long-term follow-up. *Spine.* 1980;5(3):279-291.
 62. Furlan AD, van Tulder M, Cherkin D, et al. Acupuncture and dry-needling for low back pain: an updated systematic review within the framework of the cochrane collaboration. *Spine.* 2005;30:944-963.
 63. Cotchett MP, Munteanu SE, Landorf KB. Effectiveness of trigger point dry needling for plantar heel pain: a randomized controlled trial. *Phys Ther.* 2014; 94(8):1083-1094. doi: 10.2522/ptj.20130255.
 64. Settergren R. Treatment of supraspinatus tendinopathy with ultrasound guided dry needling. *J Chiropr Med.* 2013;12(1):26-29. doi: 10.1016/j.jcm.2012.11.002.
 65. Jedrzejczak A, Chipchase LS. The availability and usage frequency of real time ultrasound by physiotherapists in South Australia: an observational study. *Physiother Res Int.* 2008;13:231-240. doi: 10.1002/pri.409.
 66. Talbott NR, Witt DW. Ultrasound imaging of the serratus anterior muscle at rest and during contraction. *Clin Physiol Funct Imaging.* 2013;33:192-200. doi: 10.1111/cpf.12012.
 67. Talbott NR, Witt DW. Ultrasound examination of the serratus anterior during scapular protraction in asymptomatic individuals: reliability and changes with contraction. *PM R.* 2014;6:227-234. doi: 10.1016/j.pmrj.2013.09.003.
 68. Koppenhaver SL, Hebert JJ, Parent EC, et al. Rehabilitative ultrasound imaging is a valid measure of trunk muscle size and activation during most isometric sub-maximal contractions: a systematic review. *Aust J Physiother.* 2009;55:153-169.
 69. Koppenhaver SL, Hebert JJ, Fritz JM, et al. Reliability of rehabilitative ultrasound imaging of the transversus abdominis and lumbar multifidus muscles. *Arch Phys Med Rehabil.* 2009;90:87-94. doi: 10.1016/j.apmr.2008.06.022.
 70. Mota P, Pascoal AG, Sancho F, et al. Reliability of the inter-rectus distance measured by palpation. Comparison of palpation and ultrasound measurements. *Man Ther.* 2013;18:294-298. doi: 10.1016/j.math.2012.10.013.
 71. Teyhen DS. Rehabilitative Ultrasound Imaging Symposium, May 8-10, San Antonio, Texas. *J Orthop Sports Phys Ther.* 2006;36(8):A1-A17.
 72. Bergmark A. Stability of the lumbar spine. A study in mechanical engineering. *Acta Orthop Scand Suppl.* 1989;230:1-54.
 73. Hodges PW, Richardson CA. Feedforward contraction of transversus abdominis is not influenced by the direction of arm movement. *Exp Brain Res.* 1997;114:362-370.
 74. Moseley GL, Hodges PW, Gandevia SC. Deep and superficial fibers of the lumbar multifidus muscle are differentially active during voluntary arm movements. *Spine.* 2002;27:E29-E36.
 75. Hodges P, Kaigle Holm A, Holm S, et al. Intervertebral stiffness of the spine is increased by evoked contraction of transversus abdominis and the diaphragm: in vivo porcine studies. *Spine.* 2003;28:2594-2601.
 76. Bø K, Stien R. Needle EMG registration of striated urethral wall and pelvic floor muscle activity patterns during cough, Valsalva, abdominal, hip adductor, and gluteal muscle contractions in nulliparous healthy females. *NeuroUrol Urodyn.* 1994;13:35-41.
 77. Sapsford RR, Hodges PW. Contraction of the pelvic floor muscles during abdominal maneuvers. *Arch Phys Med Rehabil.* 2001;82:1081-1088.
 78. Richardson CA, Hodges PW, Hides J. *Therapeutic Exercise for Spinal Segmental Stabilization: A Motor Control Approach for the Treatment and Prevention of Low Back Pain.* 2nd ed. Edinburgh: Churchill Livingstone; 2004.
 79. Whittaker JL. Abdominal ultrasound imaging of pelvic floor muscle function in individuals with low back pain. *J Man Manip Ther.* 2004;12(1):44-49.
 80. McGill S. *Low Back Disorders - Evidence-Based Prevention and Rehabilitation.* Champaign, IL: Human Kinetics; 2002.
 81. Gildea JE, Hides JA, Hodges PW. Size and symmetry of trunk muscles in ballet dancers with and without low back pain. *J Orthop Sports Phys Ther.* 2013;43:525-533. doi: 10.2519/jospt.2013.4523.
 82. Hungerford B, Gilleard W, Hodges P. Evidence of altered lumbopelvic muscle recruitment in the presence of sacroiliac joint pain. *Spine.* 2003;28:1593-1600.
 83. Kiesel KB, Uhl T, Underwood FB, et al. Rehabilitative ultrasound measurement of select trunk muscle activation during induced pain. *Man Ther.* 2008;13:132-138.
 84. D'hooge R, Cagnie B, Crombez G, et al. Lumbar muscle dysfunction during remission of unilateral recurrent nonspecific low-back pain: evaluation with muscle functional MRI. *Clin J Pain.* 2013;29(3):187-194. doi: 10.1097/AJP.0b013e31824ed170.
 85. Lee NG, Jung JH, You JS, et al. Novel augmented ADIM training using ultrasound imaging and

- electromyography in adults with core instability. *J Back Musculoskelet Rehabil.* 2011;24:233-240. doi: 10.3233/BMR-2011-0300.
86. Park SD. Reliability of ultrasound imaging of the transversus deep abdominal, internal oblique and external oblique muscles of patients with low back pain performing the drawing-in maneuver. *J Phys Ther Sci.* 2013;25:845-847.
87. Rath AM, Attali P, Dumas JL, et al. The abdominal linea alba: an anatomico-radiologic and biomechanical study. *Surg Radiol Anat.* 1996;18:281-288.
88. Sharma G1, Lobo T, Keller L. Postnatal exercise can reverse diastasis recti. *Obstet Gynecol.* 2014;123(Suppl 1):171S. doi: 10.1097/01.AOG.0000447180.36758.7a.
89. McMeeken JM, Beith ID, Newham DJ, et al. The relationship between EMG and change in thickness of transversus abdominis. *Clin Biomech.* 2004;19:337-342.
90. Hodges PW, Pengel LH, Herbert RD, et al. Measurement of muscle contraction with ultrasound imaging. *Muscle Nerve.* 2003;27:682-692.
91. De Troyer A, Estenne M, Ninane V, et al. Transversus abdominis muscle function in humans. *J Appl Physiol.* 1990;68:1010-1016.
92. Ninane V, Rypens F, Yernault JC, et al. Abdominal muscle use during breathing in patients with chronic airflow obstruction. *Am Rev Respir Dis.* 1992;146:16-21.
93. Noh DK, Lee JJ, You JH. Diaphragm breathing movement measurement using ultrasound and radiographic imaging: a concurrent validity. *Biomed Mater Eng.* 2014;24:947-952. doi: 10.3233/BME-130889.
94. Hodges PW. Changes in motor planning of feed-forward postural responses of the trunk muscles in low back pain. *Exp Brain Res.* 2001;141:261-266.
95. Cowan SM, Schache AG, Brukner P, et al. Delayed onset of transversus abdominis in long-standing groin pain. *Med Sci Sports Exerc.* 2004;36:2040-2045.
96. McPherson SL, Watson T. Training of transversus abdominis activation in the supine position with ultrasound biofeedback translated to increased transversus abdominis activation during upright loaded functional tasks. *PM R.* 2014;6:612-623. doi: 10.1016/j.pmrj.2013.11.014
97. Hides JA, Stokes MJ, Saide M, et al. Evidence of lumbar multifidus muscle wasting ipsilateral to symptoms in patients with acute/subacute low back pain. *Spine.* 1994;19:165-172.
98. Kiesel KB, Uhl TL, Underwood FB, et al. Measurement of lumbar multifidus muscle contraction with rehabilitative ultrasound imaging. *Man Ther.* 2007;12(2):161-166.
99. Sions JM, Velasco TO, Teyhen DS, et al. Ultrasound imaging: intraexaminer and interexaminer reliability for multifidus muscle thickness assessment in adults aged 60 to 85 years versus younger adults. *J Orthop Sport Phys Ther.* 2014;44(6):425-434. doi: 10.2519/jospt.2014.4584.
100. Hides JA, Richardson CA, Jull GA. Magnetic resonance imaging and ultrasonography of the lumbar multifidus muscle. Comparison of two different modalities. *Spine.* 1995;20:54-58.
101. Stokes M, Rankin G, Newham DJ. Ultrasound imaging of lumbar multifidus muscle: normal reference ranges for measurements and practical guidance on the technique. *Man Ther.* 2005;10(2):116-126.
102. Falla D, Bilenkij G, Jull G. Patients with chronic neck pain demonstrate altered patterns of muscle activation during performance of a functional upper limb task. *Spine.* 2004;29:1436-1440.
103. Jull G, Trott P, Potter H, et al. A randomized controlled trial of exercise and manipulative therapy for cervicogenic headache. *Spine.* 2002;27:1835-1843.
104. Cagnie B, Derese E, Vandamme L, Verstraete K, Cambier D, Danneels L. Validity and reliability of ultrasonography for the longus colli in asymptomatic subjects. *Man Ther.* 2009;14:421-426. doi: 10.1016/j.math.2008.07.007.
105. Lee JP, Tseng WY, Shau YW, Wang CL, Wang HK, Wang SF. Measurement of segmental cervical multifidus contraction by ultrasonography in asymptomatic adults. *Man Ther.* 2007;12:286-294.
106. Soltani AR, Kallinen M, Mälkiä E, Vihko V. Ultrasonography of the neck splenius capitis muscle. Investigation in a group of young healthy women. *Acta Radiol.* 1996;37:647-650.
107. Rezasoltani A, Ylinen J, Vihko V. Isometric cervical extension force and dimensions of semispinalis capitis muscle. *J Rehabil Res Dev.* 2002;39(3):423-428.
108. Rezasoltani A, Ali-Reza A, Khosro K-K, Abbass R. Preliminary study of neck muscle size and strength measurements in females with chronic non-specific neck pain and healthy control subjects. *Man Ther.* 2010;15:400-403. doi: 10.1016/j.math.2010.02.010.
109. Rezasoltani A, Nasiri R, Faizei AM, Zaafari G, Mirshahvelayatti AS, Bakhshidarabad L. The variation of the strength of neck extensor muscles and semispinalis capitis muscle size with head and neck position. *J Bodyw Mov Ther.* 2013;17:200-203. doi: 10.1016/j.jbmt.2012.07.001.
110. Kristjansson E. Reliability of ultrasonography for the cervical multifidus muscle in asymptomatic and symptomatic subjects. *Man Ther.* 2004;9:83-88.